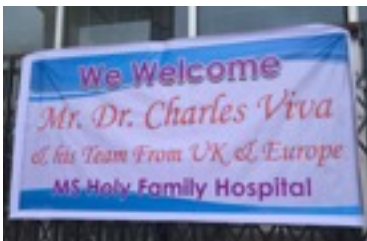



# Interplast UK Mission to Holy Family Hospital, Rawalpindi, Pakistan

10th Sep - 23rd Sep 2016 Registered Charity Number

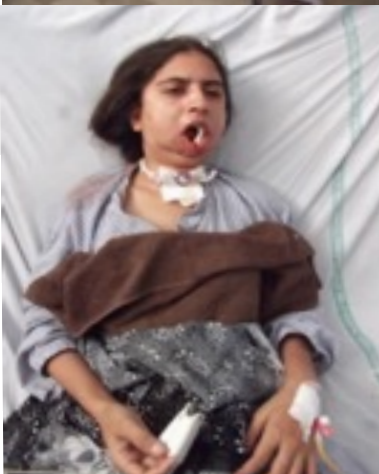
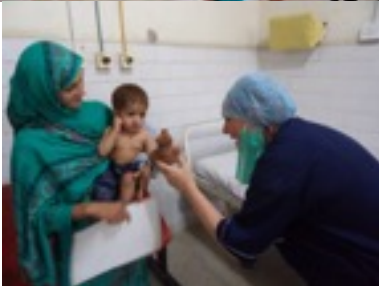
On Saturday 10th September the majority of the Interplast UK volunteers arrived at Islamabad airport. After a quick stop at the hotel it was straight to the hospital for a very warm welcome by Professor Muhammad Umar and the hospital director Dr Shafiq. Holy Family hospital was established in 1948 and supports a medical college and a nursing school, it has hosted Interplast trips previously.

Screening of the patients started that very afternoon by Mr Viva whilst some team members rested and others from the UK arrived to help list the patients for the week ahead.

It was straight to work on Sunday and involved an early arrival to unpack and organise all the medical equipment and supplies. With the help of the very accommodating local theatre staff we occupied two ENT theatres over the course of the 11 days. This meant there were some late finishes so it was great that the hotel was very comfortable providing meals morning and night.

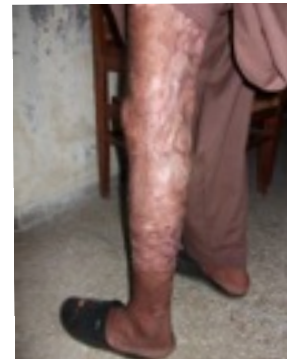On Monday the team was complete with surgeon Felix Blake and theatre nurse Anna Nagel flying in from Germany. They joined Mr Charles Viva, Georgios Pafitanis, Geraldine Bell, Dean O'Mara and Ghalib Mukadam in the surgical team with Dr David Viva, Ivy Boardman and Louise Newman as medical and nursing support on the wards and Ali Azzam and Dillon Dan as support and co-ordinators. It was Dillon's, Dean and Anna's first trip while it made up anaesthetist Ghalib's 32nd charity trip!



The first few days were quieter around the hospital as our visit coincided with EID festivities. The hospital kept us up and running and we saw many of the sacrificed goats and cows at the side of the road as we drove in on Tuesday.

In total **207 patients were screened**. For each patient seen it was really important to understand what they wanted and how their physical, social and psychological functioning was impacted. Managing their expectations and ensuring clear communication explaining the full procedure, for example taking a graft from another area, was essential and facilitated by the hospital staff as translators.

Many patients travelled great distances, up to 8 hours, presenting with a range of cases in addition to clefts, palates and burns. For one man, pictured below, he came to thank Mr Viva for his operation last year as he was now able to walk and work after being in a wheelchair and bed bound for 3 1/2 years. due to contractures. It was remarkable to see the impact the surgery had on his life.



In 11 days a total of **105 surgical procedures were performed on 77 patients:**

16 Cleft Lip Repair/Revision of Lip

19 Clef Palate Repair

2 Oronasal Fistula Repair

29 Release of Post-Burn Contractors (FTSG or SSG)

14 Steroid injections

15 Scar excisions/Skin Lesion excisions

7 Septorhinoplasty/Nasal Reconstruction

1 Hypospadias Repair

1 Bilateral TMJ Release



Above: Team photo with the theatre staff and a thank you lunch for them to enjoy

Below: The celebration meal hosted by Dr Shafiq



A special **thank you** to Javed Majid for all the organising and caring for the team, Mr Farooq and his son at our Hotel De Mall, Dr Shafiq, Professor Ajmal and all the staff who looked after us at the hospital. Many thanks to Zulifqar Haides Raja who organised patient journeys, translated and has organised the follow up care. Without surgical equipment there would have been no operations, so a huge thank you to Swann Morton for skin graft and surgical blades and Pennine healthcare for suction material and Towlers chemists from Kirbymoorside.

## 1 Tongue Tie Release

The surgical team were fantastic. In addition to the smiles created and the hands, elbows, necks and knee releases they enabled a young female to open her mouth since having a fused jaw from an accident as a child and created a nose for another young female with a harrowing story. The TMJ release held a particular anaesthetic challenge and required a joint procedure with the ENT professor to create a tracheostomy.

## Day to day

A Pakistani Breakfast at 07:30 set us up for the day which started and ended with a ward round of the post operative patients on the ENT ward and in PACU. They were cared for by the hospital staff who joined us for the ward round to facilitate the communication. The surgeons then went to see the pre-operative patients and start the list from 9am.

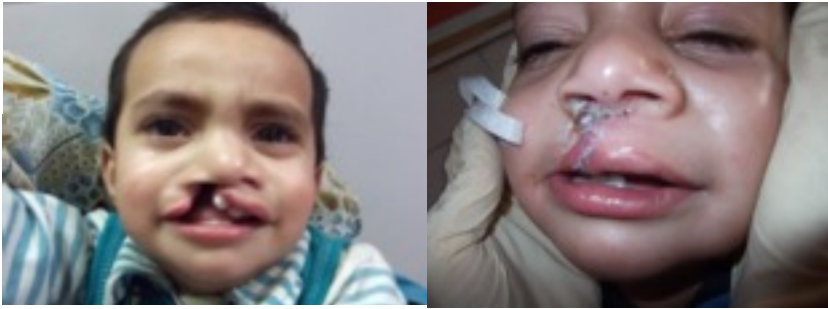
Louise and Ivy spent the days completing dressings, organising discharges and outpatients and dispensing medications. We managed to see 33 patients for dressings as outpatients. Educating the local nurses on post operative care and dressings ensured they could continue the care following our departure. Involving the parents as soon as possible was fundamental with the post operative care of CL and CP as it helped to soothe the babies and gave the parents confidence to carry on the care.

Dillon and Ali enjoyed handing out all the donations, a particularly thank you to MIND who donated lots of soft toys. It was fantastic to give them little presents of comfort and see their faces light up with excitement! There was some time to play and get to know the patients and their family which was very special.

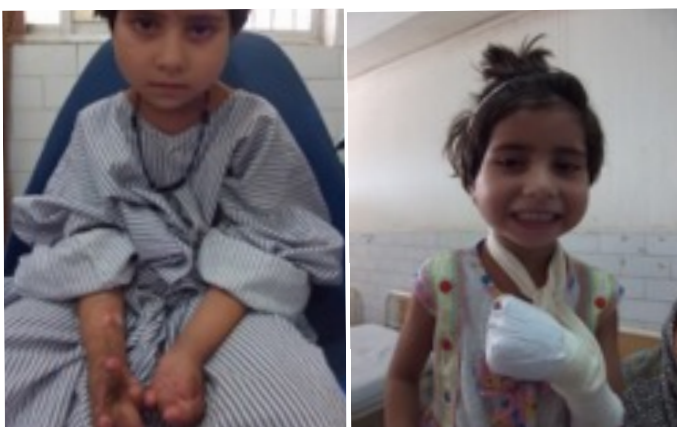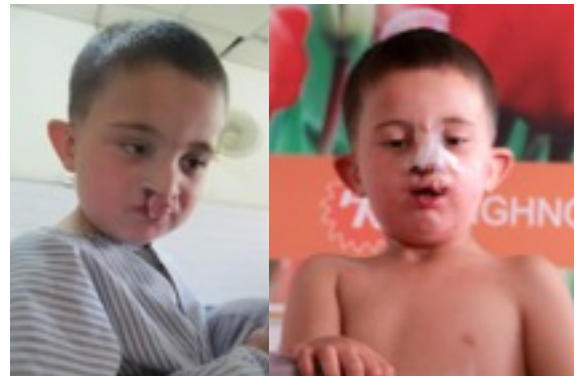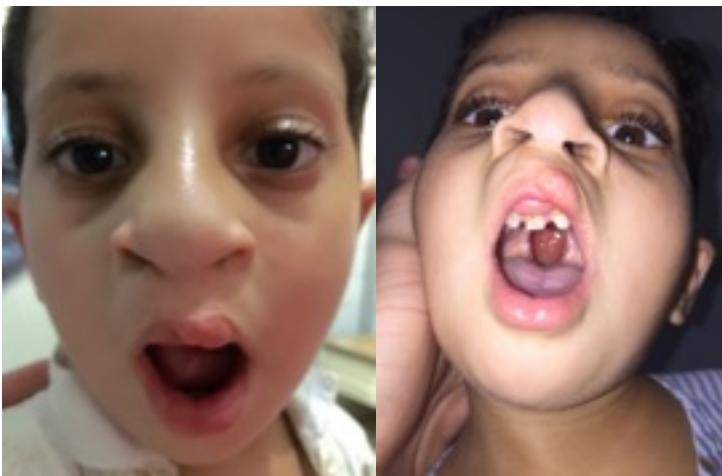
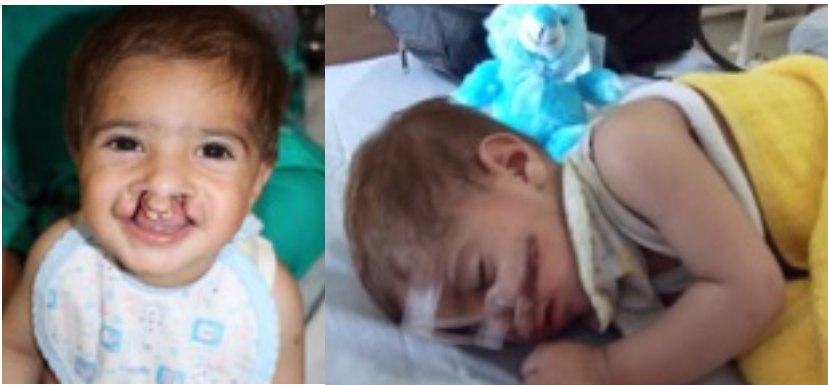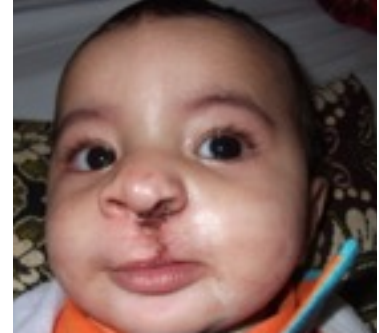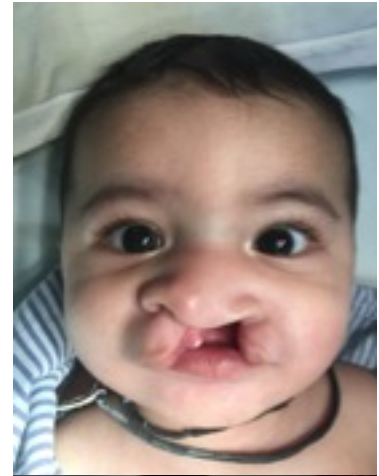
Finishing each day eating dinner together and a day trip to Taxila and a banquet picnic with a view organised by Javed Majid was a perfect way to recharge and relax on our day off as a group.

It all went by too quickly and a dinner held by Dr Shafiq in Islamabad celebrated our end of the mission. It was a privilege to be part of this team and to be able to provide the surgery and care at Holy Family Hospital. We are all very grateful to all the supporters and sponsors of Interplast who made this trip possible. **Thank you!**

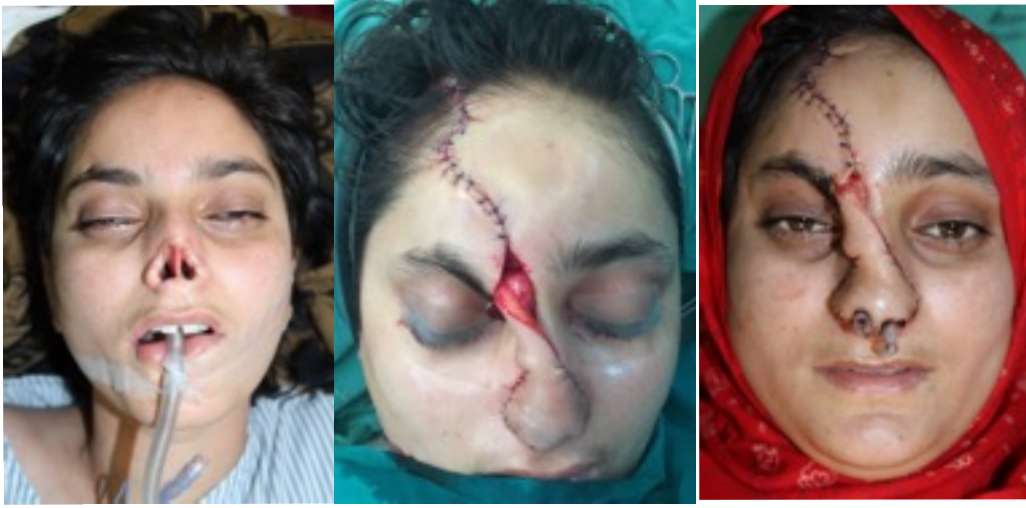# A small collection of patient photos pre and post procedures



CL and CP repairs, our youngest being 3 months

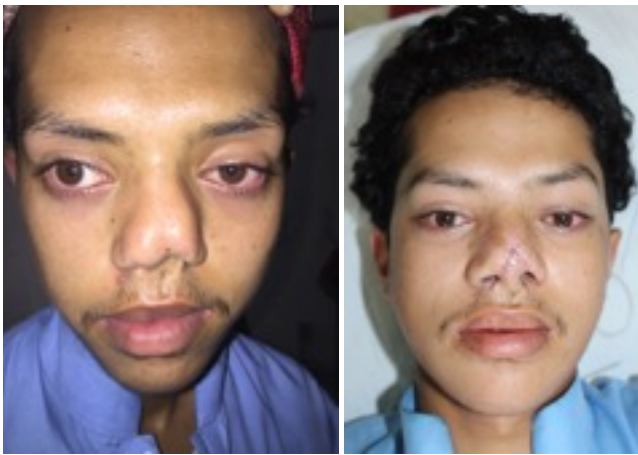

Finger releases for children, for this little girl of 6 years



5 October 2016

First part of the nasal reconstruction completed, the ENT professors will now complete the surgery.



Plaster off following a Septorhinoplasty for this 18yr male

FTSG Neck release and below a Axilla Z Plasty

